

TO EVALUATE THE ROLE OF PLATELET RICH PLASMA AS ARTIFICIAL HEMATOMA IN BONE HEALING IN CASES OPERATED WITH OPEN REDUCTION TECHNIQUE

Original Article Orthopaedics

Jeetesh Gawande¹, Sanjay Upadhyay¹

¹- Assistant Professor, Dept of Orthopaedics, LN medical College, Bhopal

Corresponding Author:

Dr Sanjay Upadhyay
Assistant Professor, Dept of Orthopaedics, LN medical College, Bhopal

Article submitted on: 03 March 2018

Article Accepted on: 12 March 2018

Abstract:

Aim: Platelets are the natural storage vessel for various growth factors and cytokines that promote blood coagulation, tissue repair, and bone healing. Platelets are the one present in the fracture hematoma which are responsible for starting the schematic orchestrated fracture healing cascade. But in cases where we open the fracture site due to various reasons we take away this precious advantage. In this study we want to study the effect of platelet rich plasma (PRP) as artificial hematoma in case where we need to open the fracture site.

Method: This randomised study was carried out in 42 patients of post traumatic acute fracture shaft of femur. These patients were divided into two groups: study group A (n= 19) which were operated with open intramedullary nailing with PRP application and control group B (n= 23) which were operated with open intramedullary nailing. Results were compared clinically by Calori's criteria and radiologically by radiological assessment of fracture healing by measuring the cortex to callus ratio on monthly follow up visits, till 6 months.

Results: On measuring and comparing the cortex to callus ratio of group A and B every month, we found a statistically significant difference in the volume of callus at 3rd month of follow up. At other months, though the group A had a better cortex to callus ratio than group B, this difference was

not statistically significant.

Conclusion: PRP has shown to increase the volume of callus formation at fracture site in case of acute fractures operated with open reduction methods and this difference was statistically significant at 3 months follow up. So PRP does have an osteogenic potential in bone healing and promote callus formation in acute fracture operated with open reduction technique.

Keywords: PRP, Artificial Hematoma, Bone healing

Introduction

Nothing gives more pleasure to an orthopaedic surgeon than seeing a well united fracture in his post operative patient. Fracture healing is a complex process with lots of variables which has been studied for long and in great detail. Still we cannot guarantee which fracture is going to unite and which is going to be nightmare for us.

Advancement in surgical techniques and newer imaging technology has made a breakthrough by allowing us to close reduce and fix the fracture. Close reduction and fixation is advantageous in many ways like it doesn't disturb the fracture hematoma, avoid soft tissue injury and devascularisation of fracture fragments. So indirect reduction methods were described which re-establish proper bone length, rotation and alignment without disturbing the fracture biology.¹ Because high priority has been given to preserve the soft tissue envelop and fracture hematoma, some author report that open reduction techniques should be avoided.² But unfortunately this is not possible every time. Inadequate reduction, soft tissue interposition, peri-articular injuries and associated neurovascular injury are the most common indications which require open reduction and fixation. Once open, the healing environment around the fracture is disturbed at the molecular level.

With recent development made in field of molecular biology and genetics, there has been lot of focus on this microenvironment around the fracture site. Though the exact pathophysiology of fracture healing is not yet completely understood, manipulation of this microenvironment around the fracture site by application of growth factors has shown promising results.³ Platelets are the natural

storage vessels for various growth factors and cytokines which are present in the fracture hematoma which starts and modulates the schematic cascade of fracture healing. Platelet derived growth factor (PDGF), Insulin like growth factor (IGF) and transforming growth factor (TGF) - β are the main growth factors released by the platelets which are involved in blood coagulation, soft tissue healing and bone mineralisation.^{4,5} Transforming growth factor - β 1 in conjunction with Bone morphogenic proteins (BMPs) released from mesenchymal stem cells trigger chondroblastic and osteoblastic differentiation and production of bone matrix.^{6,7,8} Therefore autologous platelet rich plasma is gaining popularity and working wonder in Orthopaedics. Present study aims to evaluate the role of platelet rich plasma in bone healing in acute fractures which were operated by open reduction methods. We hypothesize that the PRP can give an artificial hematoma effect and can enhance fracture healing by providing the essential growth factors in fractures operated with open reduction technique.

Materials and methods

This prospective randomised study was carried out on 42 patients with acute non-comminuted diaphyseal fracture shaft of femur, admitted in our tertiary level health care centre from 2011 to 2013. Patients were of either sex within age group 18-60 years. Patients with open fractures, associated head injury, poly-trauma patients, pathological fractures and fractures associated with bone disorders were excluded from the study. Patients were followed up for minimum 6 months.

An informed consent was obtained from all the participants for inclusion

in the study. Detailed history was taken from all the patients regarding the mode of injury and examination was done including recording of associated injuries, if any.

Standard Antero-posterior (AP) and lateral X-rays of fractured bone were done. Fractures were classified according to AO and Winkquist and Hansen classification. Patients were subjected to all relevant pre-operative investigations and were taken up for surgery as soon as they became fit for anaesthesia. Surgery was performed under spinal/general anaesthesia. Interlock nailing was done for all the cases. Patients were randomly assigned to one of the two groups using a computer generated sequence of random numbers. Study group (n=19) were treated with open reduction of fracture, fixation with interlocking nail and PRP application. Control group were (n=23) treated with open interlock nailing. All the surgeries were performed by the same surgeon.

Methodology for preparation of PRP and its usage

Platelet rich plasma was prepared in the department of blood and transfusion. On the day of surgery, 70 ml of patient's blood was withdrawn from the antecubital vein under aseptic condition. This blood was then immediately mixed with anticoagulant citrate phosphate dextrose adenine (CPDA) in a ratio 9:1 of the CPDA. Then we centrifuged this mixture at 2000 rpm for 10 mins. After the first centrifugation the blood is layered in 3 components: red blood cells (RBCs), platelets and platelet poor plasma (PPP). RBCs being the heaviest gets settled down at the bottom. Platelets were at the middle and PPP at the top. Using a long sterile broad needle the RBC layer is removed. The remaining

part is then again centrifuged at 2800 rpm for 10 mins. Now the remaining mixture is centrifuged in two layers. The supernatant is PPP and the lower layer consists of concentrated platelets. About three fourth of the supernatant is collected as PPP and the residual was PRP (around 12-14 ml).

Platelet Poor Plasma and 10% calcium gluconate was mixed (0.2-0.5 ml calcium gluconate/ml of PPP) and the solution was kept at room temperature for 12-15 minutes to make autologous thrombin. Platelet rich plasma was activated by addition of autologous thrombin (0.2 ml/ml of PRP) and subsequently calcium gluconate (0.2 ml/ml of PRP). Platelet rich plasma was activated by addition of autologous thrombin (0.2 ml/ml of PRP) and subsequently calcium gluconate (0.2 ml/ml of PRP) and was allowed to stand for 12-15 minutes at room temperature till it transformed into PRP gel. PRP gel thus formed was applied locally at the fracture site after achieving complete haemostasis. No negative suction drains were used in any patient of our study.

Figure 1 showing the centrifuge machine used.

Figure 2 shows the results of first centrifuge.

Figure 3 showing the final PRP prepared.

Follow up

Patients were discharged on 4th to 7th post operative day. Stitches were removed on the first follow up at 2 weeks. Subsequent follow ups were done monthly till 6 months. Fracture union was assessed on the basis of radiological evaluation and clinical assessment.

Clinical assessment

It was done by Calori criteria⁹ as

under:

1. Pain: at rest, on weight bearing
2. Functionality: none / insufficient; use against gravity; use against resistance; full
3. Walking: not possible; possible with orthopaedic devices; limp; partial (indicates % bearing allowed); full
4. Tests: site instability; abnormal motility; site stability but painful; full site stability, pain free
5. Muscular trophism: hypo/normo/hypertrophic (indicates centimeter circumference).

Clinical diagnosis of union was determined by the absence of pain and absence of motion at the fracture site upon manual stress testing in sagittal and coronal planes and functional recovery of range of motion of the involved extremity.

Radiological assessment

It was done by monthly cortex to callus ratio measurement.

Cortex to callus ratio: X-ray of fractured bone (AP and lateral view) was taken. Calliper was used to measure the callus to cortex width on radiograph. Maximal callus width divided by average width of the 2 cortices in close proximity to the fracture line gave the cortex to callus ratio.¹⁰ Presence of a bridging callus in three out of four cortices in AP and lateral views was considered as radiological union.

Statistical analysis

At the end of the study the data was collected and analyzed by appropriate statistical tests. Distribution of age, distribution of sex, distribution of side of fracture, and classification of fractures according to AO and Winqvist and Hansen classification

were statistically analyzed by Chi-square test. Difference in the mode of trauma between study and control group was statistically analyzed by Unpaired t-test. Results of clinical assessment by Calori criteria were statistically analyzed by Chi-square and Kruskal-Wallis test. Radiological assessment by cortex to callus ratio and time to union were statistically analyzed by ANOVA test. For all tests, probability less than 0.05 were considered as significant.

Results

Statistical tests found no significant difference between the distribution of patients in two groups with respect to age, sex, side of fracture and type of fracture and mode of trauma.

The mean time taken by the patients of group A and B to have a painless weight bearing as described by Calori was 3.47 ± 0.95 and 3.73 ± 0.98 months, respectively. On comparing these groups by Chi-square test, no significant difference was observed in any month of follow up. The mean time taken by the patients of group A and B to have full functional use was 2.53 ± 0.61 and 2.69 ± 0.63 months, respectively. On comparing these groups by Kruskal-Wallis test, no significant difference was observed in any month of follow up. The mean time taken by the patients of group A and B to walk without support was 3.58 ± 0.72 and 3.78 ± 0.75 months, respectively. On comparing these groups by Kruskal-Wallis test, no significant difference was observed in any month of follow up. The mean time taken by the patients of group A and B to have a stable pain free fracture site on fulcrum test was 4.32 ± 1.11 and 4.56 ± 1.15 months, respectively. On comparing these groups by Kruskal-Wallis test, no significant difference

was observed in any month of follow up. Because of the early initiation of physiotherapy as early as on the first post op day, we hardly saw any muscle wasting. Only five patients in the study group and five in the control group were having some muscle wasting in the first month which disappeared later in follow up. On comparing these groups by Kruskal-Wallis test, no significant difference was observed in any month of follow up.

The cortex to callus ratio was measured for the two groups at all six months of follow up. Group A

had better cortex to callus ratio than group B at all 6 month and this difference was statistically significant at third month($p=0.006$). In other months though study group had better cortex to callus ratio, this difference was not statistically significant. Radiological union was compared for the two groups. On comparing the two groups by ANOVA test no significant difference was observed in any month of follow up. No patient in our study had any allergic reaction, infection or any other complication due to PRP application.

Table 1

	Mean cortex to callus ratio of two groups in monthly follow up					
	First month	Second month	Third month	Forth month	Fifth month	Sixth month
Study Group	1.00487	1.07612	1.17065	1.27655	1.33613	1.41418
Control group	1.00289	1.06058	1.13612	1.24782	1.3116	1.41374

Figure 4 and 5 showing X-rays of two index cases. Figure 6 showing progression to radiological union in two groups in follow up months.

Figure 1 showing the centrifuge machine used



Figure 2 shows the results of first centrifuge


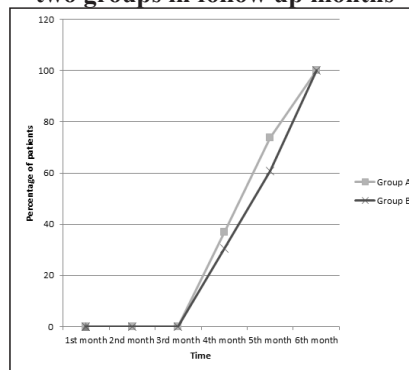


Figure 3 showing the final PRP prepared



Figure 4 showing an Index case

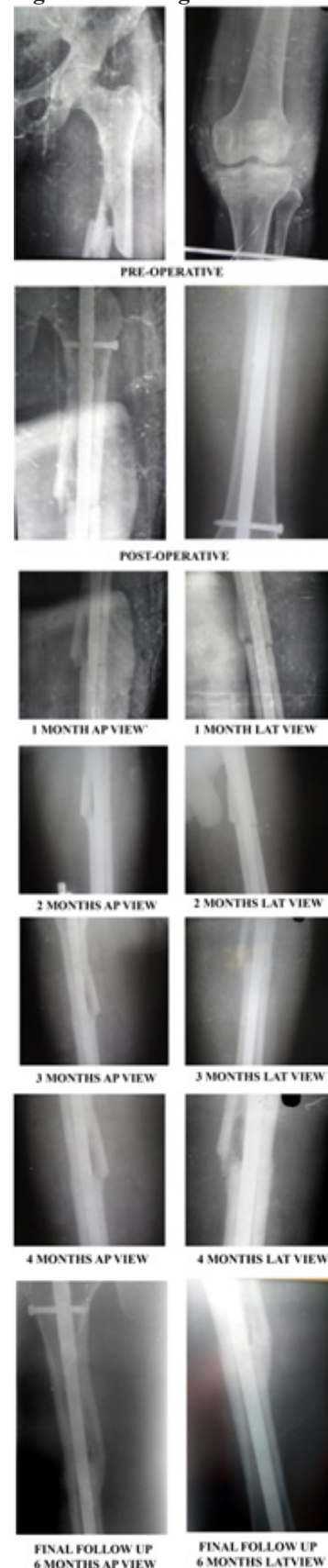
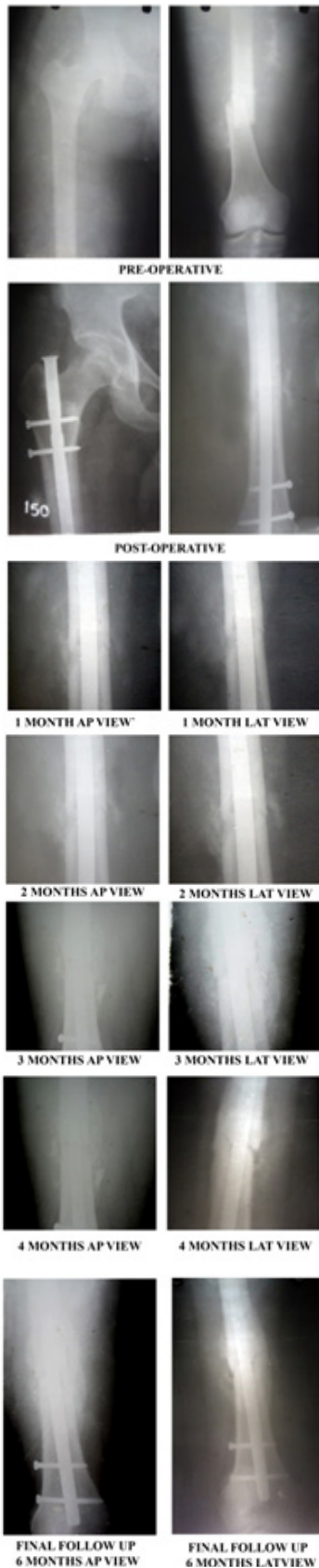
Figure 5 showing another index case**Figure 6 Progression to radiological union in two groups in follow up months**

Discussion

In orthopaedics, new research has been focused on developing new materials that may enhance bone healing, alone or in combination with other graft materials. Autografts are considered as the gold standard for enhancing fracture healing but their usage is limited by donor-site morbidity and limited supply.^{11,12,13} Problems of using allografts includes unpredictable immunogenic response in some patients and the risk of disease transmission.^{13,14} Because of these limitations, new resources are under research which can promote fracture healing. Platelet-rich plasma has shown to stimulate osteoblast proliferation in vitro and to enhance bone repair, presumably because of the high levels of autologous growth factors that do not induce immunological reaction. Another advantage of PRP is its versatility.¹⁵ It further permits local delivery of growth factors non-operatively by infiltrating the fracture site with activated liquid plasma.¹⁶ Addition of calcium gluconate promotes the gradual formation of native thrombin, mimicking the physiologic clotting process and enabling a more sustained release of growth factors.¹⁷ Alternatively, exogenous thrombin mixed with calcium gluconate can be

used to induce clotting.

In the present study we could not find any statistically significant difference in the functional results between the two groups. But the radiological assessment of cortex to callus ratio showed a better callus formation in group A than group B. This difference was clinically significant ($P=0.006$) in third month of follow up. This finding suggests that PRP application enhance fracture by enhancing callus formation. Though our end result at six month showed no difference, but this may be because of otherwise good union rate of fracture femur operated with intramedullary nailing.

Studies conducted on humans have reported having varying effect of PRP on fracture healing.^{3,18,19,20} Dallari et al¹⁸ evaluated the role of PRP in healing of tibial osteotomy in genu varum patients. They reported a significantly higher rates of osseointegration in groups treated with PRP or PRP plus stromal cells than in the control group ($p<0.005$ and $p<0.0001$, respectively). In other study done by Mariconda et al¹⁹ over long bone non unions treated with external fixation, healing rate of nonunion was 90% (18/20) in platelet gel cases and 85% (17/20) in controls ($p=0.633$). They failed to show any clinical usefulness of PRP in healing of long bone non union treated by external fixation. Study conducted by Sanchez et al²⁰ in non hypertrophic non union showed that PRP treated study group have united radiologically over a period of 12 months to 48 months (mean 15.3 months) by using preparation rich in growth factors. They concluded that PRP enhanced the healing of non hypertrophic non unions of long bones. Calori et al³ compared the efficacy of PRP and rhBMP protein 7 in healing in cases

of non-unions. They reported rhBMP protein 7 is superior to PRP in fracture healing of long bones.

Studies done in animal models for evaluating the role of PRP have shown varying effect in bone healing. Kasten et al²¹ reported positive findings within a critical size bone defect in rabbits after 16 weeks, demonstrating that the addition of PRP to a hydroxyapatite (HA) carrier was able to significantly improve the bone healing compared to the HA carrier alone. Kanthan et al²² studied the effect of PRP on rabbits in bone healing in critical size defect. They concluded that the use of PRP with bone graft significantly improves the quality of bone healing. However, the use of PRP without bone substitute does not provide adequate repair tissue and, therefore, provides little benefit when used independently. Jungbluth et al²³ also demonstrated in mini-pigs that the addition of PRP to HA improved bone defect healing at 6 weeks. Weibrich et al²⁴ assessed the effect of platelet concentration in platelet rich plasma on peri-implant bone regeneration in rabbits. Comparing the bone regeneration by flourochrome staining in 4 weeks, only significant difference ($p = 0.004$) was seen with intermediate platelet concentrations. They concluded that the platelet concentration required for a positive PRP effect on bone regeneration seemed to span a very limited range. Sarkar et al²⁵ assessed the effect of PRP on new bone formation in a critical diaphyseal long bone defect in sheep. They found that bone volume, mineral density, mechanical rigidity and histology of newly formed bone in the defect did not differ significantly between PRP treated and the control group and no effect of PRP upon bone formation was observed. Gandhi et al²⁶ studied the effect of local platelet

rich plasma delivery on diabetic fracture healing. They found that PRP delivery at the fracture site normalized the early (cellular proliferation and chondrogenesis) parameters while improving the late (mechanical strength) parameters of diabetic fracture healing. Their result suggested a role for PRP in mediating diabetic fracture healing and potentially other high risk fractures.

Simman et al²⁷ analyzed the therapeutic role of PRP in long-bone fracture healing in Lewis rats. Following 4 weeks of fracture healing, radiographic analysis demonstrated higher callus to cortex width ratio ($p < 0.05$) in the PRP group. Their results suggested that PRP accelerates bone fracture healing of rat femurs via modulation of TGF- β 1 and BMP-2 growth factor expression. Gumieiro et al²⁸ evaluated the influence of PRP addition on bone repair of circular defects created in irradiated tibiae of rats by histometric analysis. They concluded that the addition of platelet-rich plasma had a beneficial effect in the initial cellular regeneration period and enhance bone formation in later periods when compared to control. Ali Rezaie et al²⁹ studied the effects of PRP on healing of femoral cancellous bone defect in diabetic rabbit. They concluded that PRP provides a rapid regeneration of bone defects in femoral cancellous bone in diabetic rabbits. Yang et al³⁰ in studied the effect of platelet rich plasma on fracture healing in rabbits. They concluded that PRP accelerates bone fracture healing of rat femurs by increasing expression of type I collagen and the number of Bone Island. Batista et al³¹ performed a comparative analysis of the effects of platelet-rich plasma and centrifuged bone marrow aspirate on the induction of bone healing in rabbits. They

concluded that after four weeks, the platelet-rich plasma promotes a greater amount of bone consolidation than the bone marrow aspirate concentrate. Ahmad Asghari et al³² studied the effect of PRP on healing of tibial bone defect in rabbit. Their results showed that platelet rich plasma could increase the bone healing in middle shaft of tibia defect in rabbit.

The reason for the failure of PRP in some studies might be due to inability to provide osteoconductive effects. It was assumed that PRP alone cannot induce bone formation but can enhance osteogenesis in the presence of precursors cells by providing essential growth factors.^{33,34} This explains the success of PRP seen in cancellous defects or in combination with autogenous grafts. However, this limitation will prevent Platelet rich plasma from becoming a good alternative in reconstruction of major diaphyseal defects with low regenerative potential. In the present study, few limitations were identified but could not be avoided. The main issue was the small number of subjects. A larger study involving more subjects would be ideal; but the results obtained here do serve as a preliminary research. Therefore, this study can justify future research undertakings using larger sample size and different doses of PRP to see its effectiveness. It is possible that with larger numbers significant differences could be found.

By conducting this study, we have reached on an inference that PRP can be used in fresh fractures, which the surgeon thinks might be at a risk of healing problems. Intra-operative decisions of opening the fracture site due to various reasons can be made without much worrying about the loss of fracture hematoma as PRP can

compensate for it. With the advances made in the field and table top centrifuge machines available at low costs the procedure can be standardized and used as and whenever needed in orthopaedic trauma surgery to enhance bone healing.

Conclusion

In the light of findings of the present study, we conclude that PRP does have an osteogenic potential in bone healing and promote callus formation in acute fracture operated with open reduction technique. The cocktail of growth factors of PRP can provide an artificial hematoma effect in these cases to compensate for the loss of natural hematoma of bone fracture. The easy preparation protocols, biosafety, versatility and low preparation cost have encouraged the therapeutic use of PRP for stimulation of tissue healing and bone regeneration.

References

1. Leunig M, Hertel R, Siebenrock KA, Ballmer FT, Mast JW, Ganz R. The evolution of indirect reduction techniques for the treatment of fractures. *Clin Orthop Relat Res*. 2000; (375):7-14.
2. Bone LB, Johnson KD. Treatment of tibial fractures by reaming and intramedullary nailing. *J Bone Joint Surg Am*. 1986; 68(6):877-887
3. Calori GM, Tagliabue L, Gala L, d'Imporzano M, Peretti G, Albisetti W. Application of rh-BMP-7 and platelet rich plasma in the treatment of long bone non-unions: a prospective randomised clinical study on 120 patients. *Injury* 2008;39:1391-402.
4. Anitua E. Plasma rich in growth factors: preliminary results of use in the preparation of future sites for implants. *Int J Oral Maxillofac Implants* 1999;14:529-35.
5. Marx RE, Carlson ER, Eichstaedt RM, Schimmele, Strauss JE, Georgeff Kr. Platelet-rich plasma: growth factor enhancement for bone grafts. *Oral Surg Oral Med Oral Pathol Oral Radiol Endod* 1998;85:638-46.
6. Roldan JC, Jepsen S, Miller J, Freitag S, Rueger DC, Acil Y. Bone formation in the presence of platelet-rich plasma vs. bone morphogenetic protein-7. *Bone* 2004;34:80-90.
7. Kim CS, Kim JI, Kim J, Choi SH, Chai JK, Kim CK. Ectopic bone formation associated with recombinant human bone morphogenetic proteins-2 using absorbable collagen sponge and beta tricalcium phosphate as carriers. *Biomaterials* 2005;26:2501-7.
8. Xu SW, Yu R, Zhao GF, Wang JW. Early period of fracture healing in ovariectomized rats. *Chin J Traumatol* 2003;6:160-6.
9. Calori GM, D'Avino M, Tagliabue L, Albisetti W, d'Imporzano M, Peretti G. An ongoing research for evaluation of treatment with BMPs or AGFs in long bone non-unions: protocol description and preliminary results. *Injury* 2006;37:S43-50.
10. Sano H, Uthoff HK, Backman DS. Correlation of radiographic measurements with biomechanical Study results. *Clin Orthop Relat Res* 1999;268:271-8.
11. Desai BM. Osteobiologics. *Am J Orthop* 2007;36:8-11.
12. Laurencin CT, Khan Y, El-Amin SF. Bone graft substitutes. *Expert Review Medical Devices* 2006;01:49-57.
13. Toolan BC. Current concepts review. *Orthobiologics*. *Foot Ankle Int* 2006;27:561-6.
14. De Long WG, Einhorn TA, Koval K, McKee M, Smith W, Sanders R et al. Current concepts review: Bone grafts and bone graft substitutes in orthopaedic trauma surgery. *J Bone Joint Surg AM* 2007;89:649-658.
15. Anitua E, Sanchez M, Orive G, Andia I. The potential impact of the preparation rich in growth factors (PRGF) in different medical fields. *Biomaterials* 2007;28:4551-60.
16. Anitua E, Sanchez M, Orive G, Andia I. Delivering growth factors for therapeutics. *Trends Pharmacol Sci* 2008;29:37-41.
17. Tsay RC, Vo J, Burke A, Eisig SB, Lu HH, Landesberg R. Differential growth factor retention by platelet-rich plasma composites. *J Oral Maxillofac Surg* 2005;63:521-28.
18. Dallari D, Savarino L, Stagni C, Cenni E, Cencchi A. Enhanced tibial osteotomy healing with use of bone grafts supplemented with platelet gel or platelet gel and bone marrow stromal cells. *J Bone Joint Surg Am* 2007;89:2413-20.
19. Mariconda M, Cozzolino F, Cozzolino A, D'Agostino E, Bove A, Milano C. Platelet gel supplementation in long bone nonunions treated by external fixation. *J Orthop Trauma* 2008;22:342-5.
20. Sanchez M, Anitua E, Cugat R, Azofra A, Guadilla J, Seijas R. Nonunions treated with autologous preparation rich in growth factors. *J Orthop Trauma* 2009;23:52-9.
21. Kasten P, Vogel J, Geiger F, Niemeyer P, Luginbuhl R, Szalay K. The effect of platelet-rich plasma on healing in critical-size long-bone defects. *Biomaterials*

- 2008;29:3983-92.
22. Kanthan SR, Kavitha G, Addi S, Choon DSK, Kamarul T. Platelet rich plasma (PRP) enhances bone healing in non-united critical sized defects: A preliminary study involving rabbit model. *Injury Int J Care Injured* 2011;42:782-9.
 23. Jungbluth P, Wild M, Grassmann JP, Ar E, Sager M, Herten M et al. Platelet-rich plasma on calcium phosphate granules promotes metaphyseal bone healing in minipigs. *J Orthop Res* 2010;28:1448-55.
 24. Weibrich G, Hansen T, Klies W, Buch R, Hitzler WE. Effect of platelet concentration in platelet rich plasma on peri-implant bone regeneration. *Bone* 2004;34:665-71.
 25. Sarkar MR, Augat P, Shefelbine SJ, Schorlemmer S, Huber-Lang M, Claes L. Bone formation in a long bone defect model using a platelet rich plasma loaded collagen scaffold. *Biomaterials* 2006;27:1817-23.
 26. Gandhi A, Doumas C, O'Connor JP, Parsons JR, Lin SS. The effects of local platelet rich plasma delivery on diabetic fracture healing. *Bone* 2006;38:540-6.
 27. Simman R, Hoffmann A, Bohinc JR, Peterson WC, Russ AJ. Role of platelet rich plasma in acceleration of bone fracture healing. *Ann Plast Surg* 2008;61:337-44.
 28. Gumieiro EH, Abrahao M, Jahn RS, Segretto M, Alves MT. Platelet-rich plasma in bone repair of irradiated tibia of wistar rats. *Acta Cir Bras* 2010;25:257-63.
 29. Rezaie A, Mousari G, Mohajeri D, Sardrohi VG. Effect of autogenous platelet rich plasma on femoral cancellous bone defect healing in alloxan induced diabetic rabbits. *Aust J Basic & Appl Sci* 2011;5:800-8.
 30. Hai-yang Z, Chen W, Zhen W. Role of autologous platelet rich plasma on fracture healing in rabbits. *J Clin Rehab Tissue Engineering Res* 2011;15:4415-8.
 31. Batista MA, Leivas TP, Rodrigue CJ, Arenas GCF, Belitardo DR, Guarniero R. comparison between the effects of platelet rich plasma and bone marrow concentrates on defect consolidation in rabbit tibia. *Clinics* 2011;66:1787-92.
 32. Asghari A, Issabeagloo E, Khanmohammadi M. Evaluations of histomorphometrical property of platelet rich plasma on tibial bone defect healing on rabbit. *Annals of Biological Research* 2012;3:2642-5.
 33. Schlegel KA, Donath K, Rupprecht S, Falk S, Zimmermann R, Felszeghy E et al. De novo bone formation using bovine collagen and platelet-rich plasma. *Biomaterials* 2004;25:5387-93.
 34. Froum SJ, Wallace SS, Tarnow DP, Cho SC. Effect of platelet-rich plasma on bone growth and osseointegration in human maxillary sinus grafts: three bilateral case reports. *Int J Periodont Restor Dent* 2002;22:45-53.